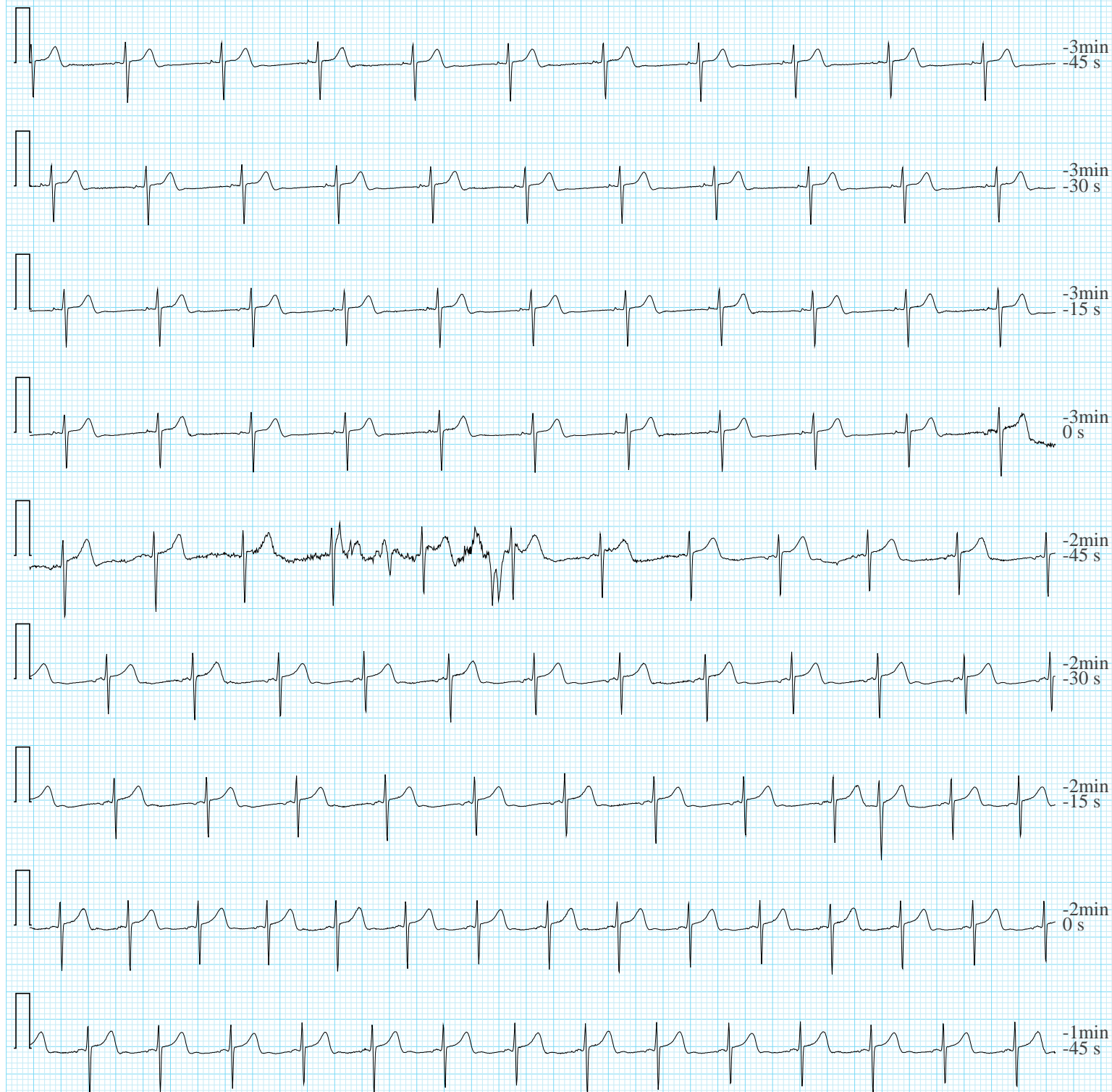


Patient:	0.000000
Age:	40
Weight:	80

Report by:	xxxx yyyy
Annotation:	Preskok
Time:	22. 07. 2016 08:30:54
Timestamp:	34844.985302s
File name:	EB-26-0C-6B-33-96
File start:	21. 07. 2016 22:50:10

0s 1s 2s 3s 4s 5s 6s 7s 8s 9s 10s 11s 12s 13s 14s 15s

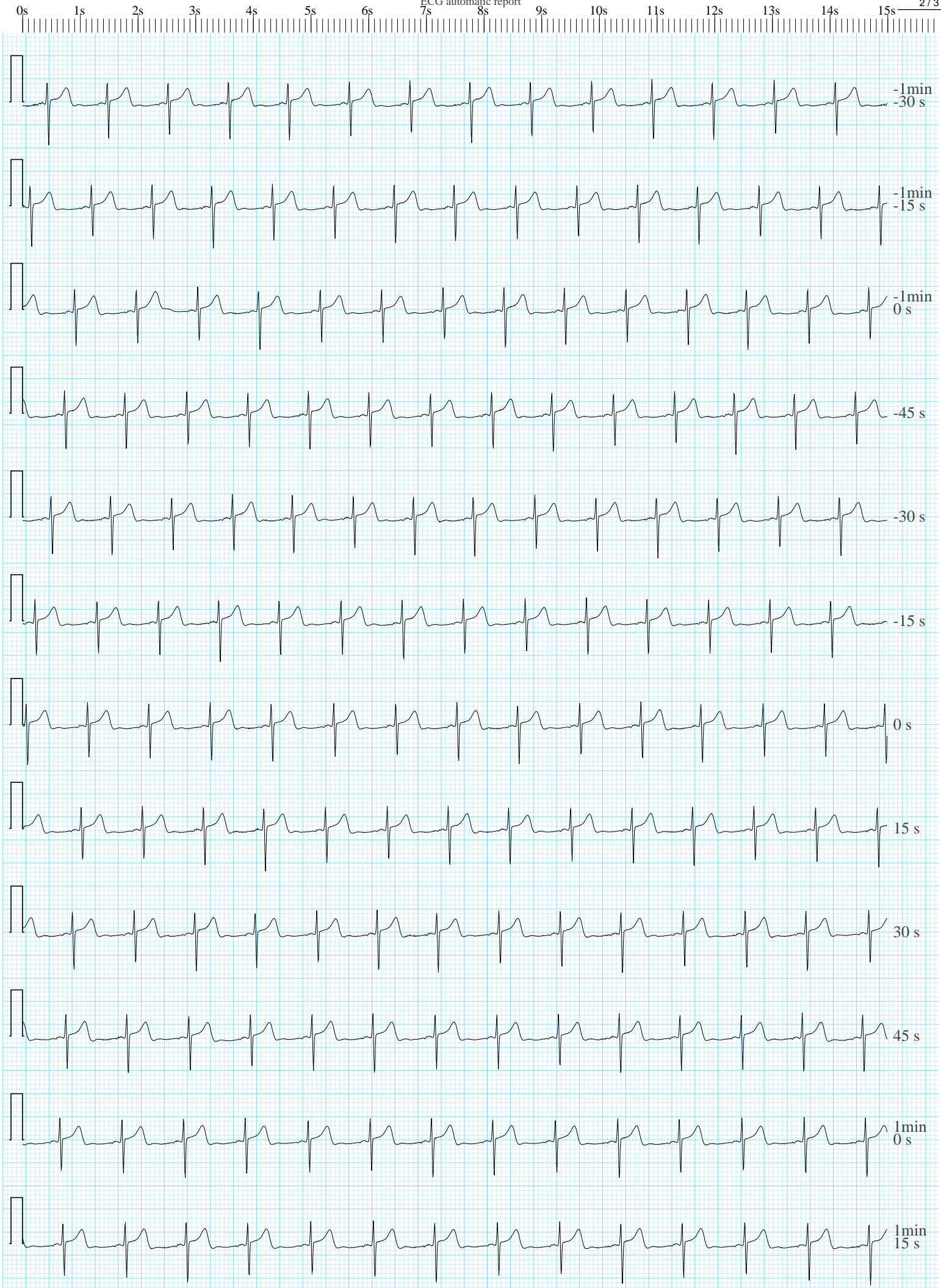
Event: Preskok at: 22. 07. 2016 08:30:54 [MobEcg:unknown, unknown]



[10mm/mV] [12.5mm/sec] raw data

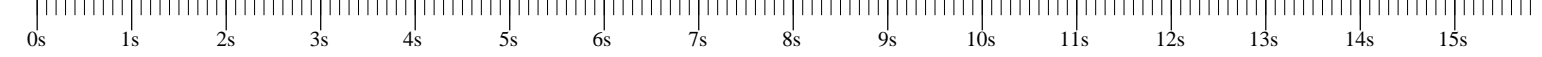
Patient: 0.000000

0s 1s 2s 3s 4s 5s 6s 7s 8s 9s 10s 11s 12s 13s 14s 15s

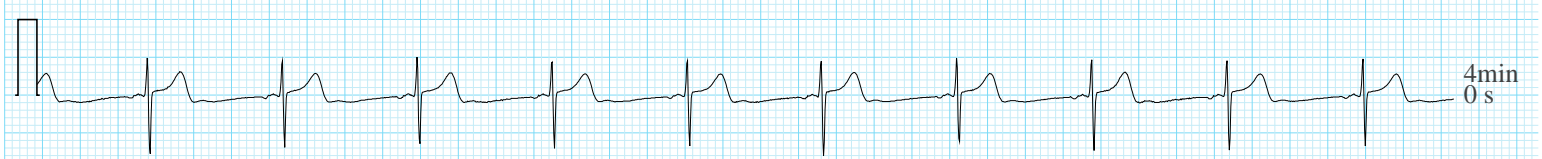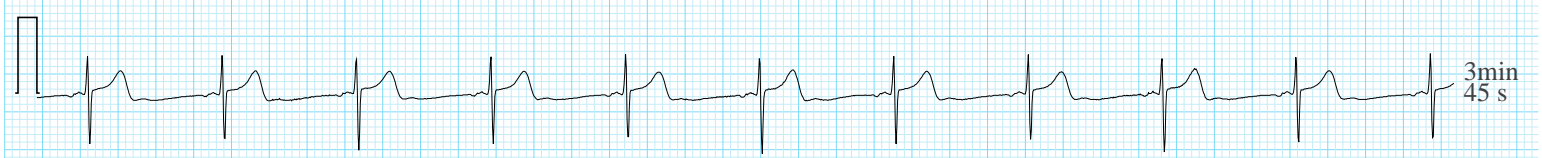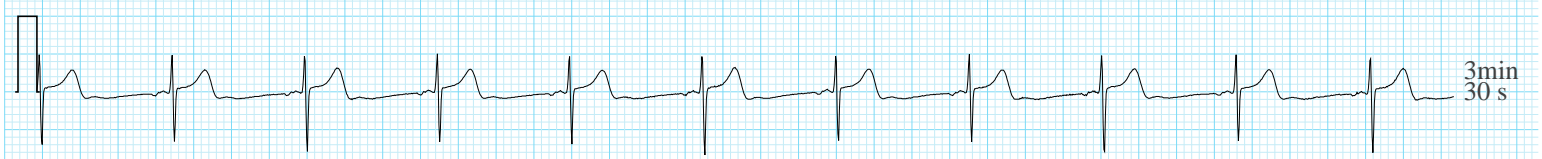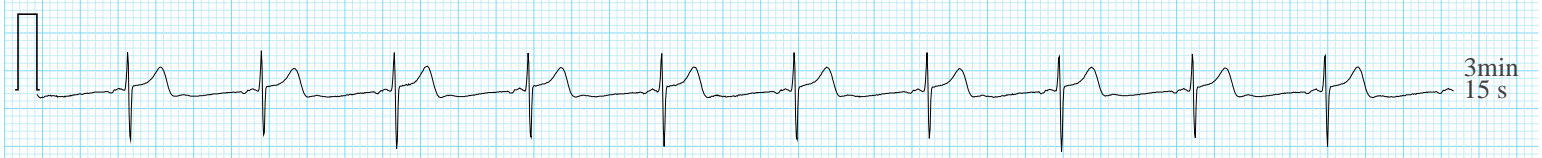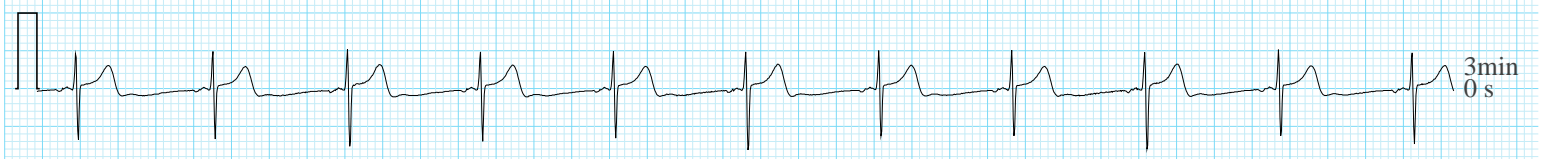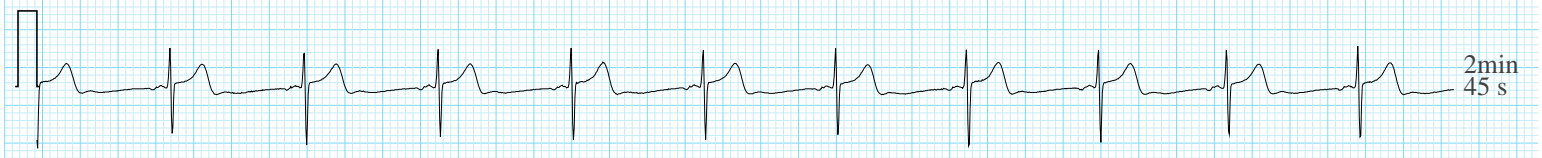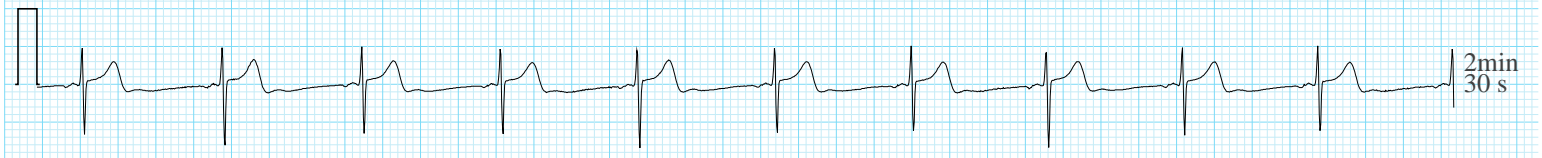
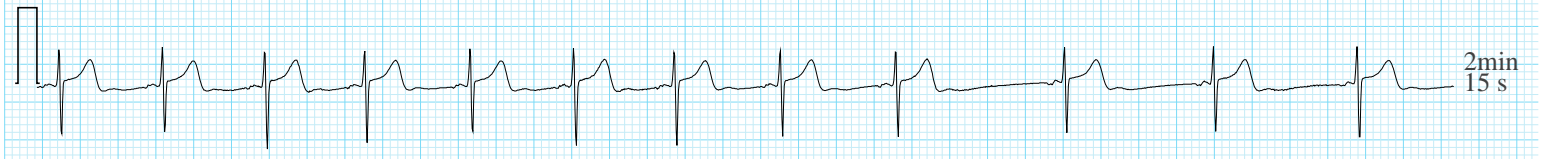
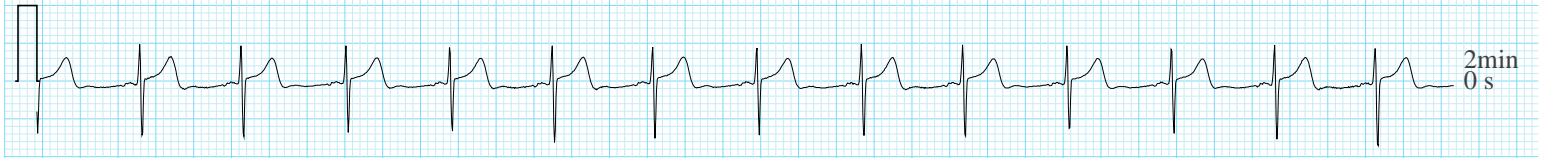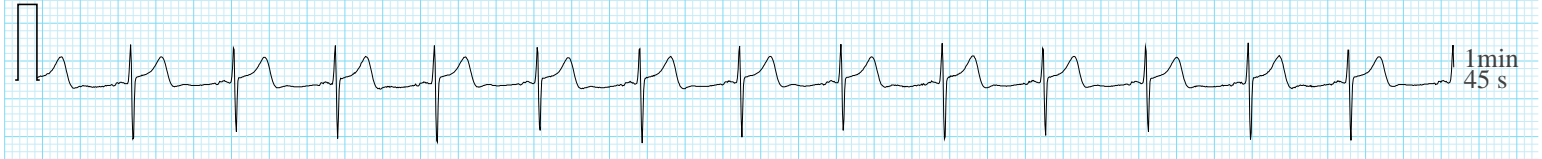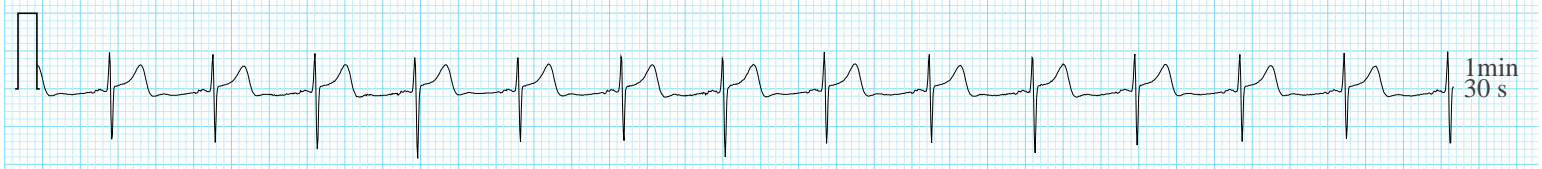


[10mm/mV] [12.5mm/sec] raw data

Patient: 0.000000



0s 1s 2s 3s 4s 5s 6s 7s 8s 9s 10s 11s 12s 13s 14s 15s



[10mm/mV] [12.5mm/sec] raw data

Patient: 0.000000

0s 1s 2s 3s 4s 5s 6s 7s 8s 9s 10s 11s 12s 13s 14s 15s